

Management of Hemorrhage in Minor Dental Operations- A Systematic Review

Suhael Ahmed

ABSTRACT

Introduction: Hemostasis is the physiological process where in bleeding is stopped at the site of an injury while maintaining normal blood flow elsewhere in the circulation. Hemostatic plug formation is the first step in this process. Blood is maintained in its fluid state by endothelium, but in case of a damaged vessel, components of the subendothelial matrix are exposed to the blood. Many components activate the two main processes of hemostasis to initiate blood clot formation, composed primarily of fibrin and platelets. This process is activated in seconds of injury but must remain localized to the site of injury. Hemorrhage can be a deterrent during surgical procedures and controlling it could be a challenging proposition. Causes for intraoperative hemorrhage may vary considerably and may be dependent on various factors from anatomical to physiological to iatrogenic.

Aims: This review focuses on various strategies to manage expected and unexpected bleeding during minor oral surgical procedures. Clinically relevant anatomy, physiology, pharmacology, and surgical and interventional radiology techniques to manage bleeding will be outlined and an algorithm for management of major vessel injury will be presented.

Methods: We conducted a search on pubmed, saudi digital library and the cochrane central register of controlled trials databases applying relevant MESH terms from the year 2000 to 2020. We identified studies by screening independent reviewers using the following selection criteria: bleeding, patients undergoing a minor dental operation, original studies and hemostatic intervention

Results: 475 articles were featuring the terms we used for search. 40 articles were shortlisted. Ten articles were included in the final review, after evaluation. We found that recent studies believe that HDD is a very effective material of dressing for hemostasis. Along with its hemostatic action, it acts as a pain reliever and also increases the ability to heal.

Conclusion: Any minor dental procedure can cause bleeding as a complication post-operatively. Management of the complication is based on how correct the diagnosis is. Referral to a local emergency unit is indicated in some cases when the bleeder is not apparent and the dentist cannot manage the case. So, a good practitioner should know the local services in the region of his work.

Keywords: dental, hemorrhage, hemostasis, Systematic reviews, surgical and minor.

Oral and Maxillofacial Pathology Journal (2021): <https://www.ompj.org/archives>.

INTRODUCTION

Minor dental producers such as dental extraction are performed for a wide variety of reasons, but most commonly to extract teeth which have become non restorable due to decay, disease or trauma, especially when they are associated with toothache^{1,2}.

Haemostasis is a normal process to occur immediately after minor dental producers like tooth extraction which we could define in balancing between fibrinolytic factors and haemostatic system with three steps, vascular spasm of blood vessels and smooth muscles, aggregation of platelets to form a plug and coagulation sequence by extrinsic and intrinsic factors³.

Interruption of this process may be caused by some medical conditions and medications⁴. Knowledge of the clinician of the normal consequence helps in detecting the high risk of bleeding

Department of oral and maxillofacial surgery, Faculty of Dentistry, Riyadh Elm University, Riyadh, Saudi Arabia.

Corresponding Author: Suhael Ahmed, Faculty of Dentistry, Riyadh Elm University, Riyadh, Saudi Arabia. Email Id: drsuhail@riyadh.edu.sa.

How to cite this article: Ahmed S. Management of Hemorrhage in Minor Dental Operations- A Systematic Review. Oral Maxillofac Pathol 2021; 12(2): 63-68

Source of Support: Nil

Conflict of Interest: None

complications as an overaction of fibrinolysis or underreaction of clotting factors that may be caused by systemic diseases^{7,8}.

Anti-fibrinolytic agents used to manage to bleeding in patients with congenital disorders is considered highly effective

and less expensive compared to the concentration of clotting factors^{9,10}. Many regimens of treatment have been used to manage complications post operatively such as pressure pack, sutures, anti-fibrinolysis agents, plasma rich platelets, fibrin sealant dressing and powder clot^{1,11,12}. This review focuses on various strategies to manage expected and unexpected bleeding during minor oral surgical procedures. Clinically relevant anatomy, physiology, pharmacology, and surgical and interventional radiology techniques to manage bleeding will be outlined and an algorithm for management of major vessel injury will be presented.

MATERIALS AND METHODS

We conducted this systematic review of the literature to discuss which of the hemostatic methods are effective in preventing hemorrhage in patients, who are undergoing minor dental operations. We followed the PRISMA checklist (Preferred Reporting Items in Systematic Reviews and Meta-Analyses).

Selection Criteria

Participants: studies reported:

1. Management of bleeding in patients undergoing minor dental operations such as tooth extraction, cyst excision, alveoloplasty

Table 1: Patients under coumarin treatment undergoing dental extractions reported by

| Group | 1 | 2 | 3 | 4 | 5 |
|--|--------------|--------|--------------|--------|-------|
| INR | 1 . 5 – 1.99 | 2–2.49 | 2 . 5 – 2.99 | 3–3.49 | >3.5 |
| INR mean | 1.74 | 2.25 | 2.63 | 3.28 | 3.8 |
| No. of patients | 59 | 78 | 59 | 30 | 23 |
| Gender | | | | | |
| M | 33 | 41 | 35 | 23 | 13 |
| F | 26 | 37 | 24 | 7 | 10 |
| Age range (years) | 40–93 | 37–81 | 41–90 | 40–78 | 39–86 |
| No. of dental extractions | 151 | 167 | 127 | 55 | 43 |
| Maxilla | 76 | 104 | 72 | 33 | 28 |
| Mandible | 75 | 63 | 55 | 22 | 15 |
| Causes of extraction | | | | | |
| Periodontitis | 116 | 134 | 91 | 44 | 38 |
| Deep caries | 35 | 33 | 36 | 11 | 5 |
| No. of postoperative bleeding | 3 | 10 | 9 | 5 | 3 |
| INR mean (patients with post-operative bleeding) | 1.66 | 2.24 | 2.77 | 3.22 | 4.01 |
| Site of bleeding | 3 | 6 | 6 | 2 | 1 |
| Maxilla | | | | | |
| Mandible | 0 | 4 | 3 | 3 | 2 |

and minor trauma.

2. Studies that included patients taking anticoagulant medication such as warfarin, undergoing minor dental surgical procedures other than extractions and management of bleeding in medically compromised patients with increased bleeding tendency because of chronic diseases as liver or renal disease or genetic bleeding disorders.
3. Animal studies, in vivo and reviews, were excluded.
4. No restriction on language, race, religion, and age.

Data Sources and Search Methods

We performed a literature search on pubmed, embase, saudi digital library and the Cochrane Central Register of Controlled Trials databases. we searched for articles using specific search terms for bleeding or hemorrhage, specific hemostatic agents and bleeding control.

Selection of Studies:

We reviewed title and abstract followed by full-text review, assessment of quality and data extraction. Every study was assessed independently by reviewers. We solved disagreements by consultation between all. When necessary, one of the team contacted the corresponding authors of the article.

The quality of the articles included was assessed using the Jadad Tool. In brief, 6 domains (namely sequence generation, allocation concealment, blinding, incomplete outcome data, selective outcome reporting, and other issues) were evaluated according to what was reported in the study. Then, a judgment of the risk of bias (high, low or unclear) was assigned to each domain.

RESULTS:

After the removal of duplicates, our search found out 475 potentially relevant studies. Titles and abstracts screening eliminated 459 studies, resulting in 16 articles for a full-text screening. 6 other studies were excluded at this stage. They were with no full-text available. Thus, 10 studies are included in this systematic review.

DISCUSSION:

As the incidence of having post-operative bleeding increases in patients receiving oral anti-coagulants or anti-platelet therapy, a novel generation HDD of haemostatic can manage post-operative bleeding incidence in cases of tooth extraction treated with oral anticoagulants according to international normalized ratio.

Blinder et al⁷, has worked on 249 patients who are receiving an oral anticoagulant therapy and have got 543 teeth extraction and divided into 5 groups which are: Group 1 with INRs of 1.5-1.99, Group 2 with INRs of 2- 2.49, Group 3 with INRs of 2.5-2.99, Group 4 with INRs of 3-3.49 and Group 5 with INRs more than 3.5. we usually measure the INR on the day of the operation. Silk sutures used with gelatin sponge may achieve haemostasis.

Of 249 patients, 30 had bleeding post operatively with a percentage 12%

- Group 1: 3 patients 5% complained of bleeding
- Group 2: 10 patients 12.8%
- Group 3: 9 patients 15.2 %
- Group 4: 5 patients 16.6%
- Group 5: 3 patients 13%

There was no significant or apparent difference between the 5 groups (table 1),

Most studies could perform teeth extractions without the need to modify the oral anticoagulant therapy as was thought in the past that one has to stop the drugs 2 to 4 days before the operations. Sutures and gelatin sponge can achieve full hemostasis and prevent bleeding. Ferraris and Swanson¹³ suggested that aspirin be stopped before any operations. Lawrence et al¹⁴ had a recommendation of aspirin therapy continuity in case of bleeding time within a normal range, so there is a need to investigate PT, INR, time of bleeding, and Time of clotting before deciding the operation. Shok kumer et al³ mentioned that sites receiving HDD had a good result in healing of wounds and fewer complications as compared with the control site group and the results were similar to those of the paper reported by Malliquist JP et al¹⁵

* Types of hemorrhage after tooth extraction are classified:

According to the time of occurrence hemorrhage classified into¹⁶:

- primary: bleeding occurs during surgery⁸.
- reactionary : 3 hours after extraction due to vasoconstriction stop⁸.
- secondary: days after the procedure due to infection.⁸

Or according to the affected site⁸ as follows:

- bony tissue
- vascular tissue
- soft tissue

Management of immediate post surgical bleeding: immediately after minor surgery particularly tooth extraction, a dentist should apply pressure on the surfaces of alveolus in the region of the socket. The first step to achieve haemostasis is to compress on the Bucco-lingual plate, this method which called digital pressure should be done immediately after extraction, to cover the socket we may use a rolled piece of sterile cotton and ask the patient to press on it or using the finger for several minutes to create the wanted pressure. The clot which starts at the base of the socket may be got by this pressure, we should ensure that the cotton will not remove it. With the removal of the cotton piece, we should have no fresh blood. However it is primarily important to identify the source of bleeding and determine if its originating from bone, vessels or soft tissue.

The patient should be given instructions on how to manage the stage after haemostasis has occurred in order not to have a secondary hemorrhage. Instructions are given verbally to the patient and

his fellow as it is important to ensure the safety of this stage especially in high-risk patients like smokers. In some cases, it is good to have the instructions written to be read at any time.

Patients sedated for treatment should have the instruction in a session before the operation or before it as the patient has the right to get precise information to skip this stage safely.

Diagnosis of the cause and site of bleeding should be done if pressure cannot stop the bleeding. Because of high vascularity of the tissues in the oral cavity, soft tissues are considered a common site for hemorrhage. Any tear in the mucosal layer of inflammation may cause prolongation of the hemorrhage, and it is therefore advisable to use vasoconstrictor with local anesthesia. A granulation tissue at the base of the socket may be complicated from wide spread infections and that results in profuse bleeding and interruption of the clotting process¹⁷.

Suturing equipment:

Sutures most often prove to be sufficient to control the ooze from tissues. There are different sizes and materials of sutures which can be used which are classified as braided or monofilament, Resorbable or non- resorbable, synthetic or natural .

The commonly used suture in intra- oral wounds is 3.0 on a 1/2 circle with a curved needle and a resorbable material as UNICRYL (Fig. 3) which is made of polyglactin. This can affect a 6 to10 day healing periodess. However, using a horizontal mattress suture gives an appropriate closure of the socket.

Chemical hemostatic agents:

Agents such as tranexamic acid, ferric sulphate and silver nitrate must be available in a clinical set up.

Tranexaemic acid:

Tranexamic acid was approved by the FDA in 1986 for short term use (2–8 days) as an injection to reduce or prevent bleeding during tooth extraction in patients with hemophilia. Tranexamic acid 4.8% is an antifibrinolytic oral rinse that facilitates clot formation by inhibiting the activation of plasminogen to plasmin. Plasmin prevents the clotting process from initiating fibrinolysis. Tranexamic acid solution may be used as a mouthwash postoperatively and has been shown to enhance clotting in patients with coagulopathies or anticoagulant therapy. Ramstrom et al showed a significant reduction in postoperative bleeding with a 10-mL rinse, four times a day for 7 days postoperatively.¹⁸ Choi et al showed a

Table 2: Comparison of healing between Hemcon dental dressing (HDD) versus control sites reported by KUMAR et al

| | | improved healing | | mean hDD improved healing versus Control | p-value |
|----------|------------------|------------------|---------|--|-----------|
| | | hDD | Control | | |
| At day 1 | Improved healing | 22 | 0 | 2.73 ± 0.449 | < 0.0001* |
| | Same as control | 8 | 30 | | |
| At day 3 | Improved healing | 30 | 0 | 2.4 ± 0.498 | < 0.0001* |
| | Same as control | 0 | 30 | | |

Unpaired t-test, *Statistically significant

significant decrease in bleeding during maxillary surgery after a bolus of tranexamic acid was given preoperatively¹⁹.

Ferric sulfate: It has a wide range of uses in the dental clinic such as being a part of gingival retraction technique to impress the work in crown/bridge, during pulpotomy as a haemostatic substance, use as a control measure of after-extraction bleeding not common but it may help in cases with a tear in the mucosa.



Fig. 1: Hemcon Dental Dressing (HDD).



Fig. 2A and 2B: Absorbable Gelatin Sponge.



Fig 3: 4.0 UNICRYL - Braided and Coated glycolide homopolymer violet synthetic absorbable suture

Silver nitrate: Indications of use are when sutures or finger pressure aren't suitable and after the mucosal biopsy is taken from hard palate. It is considered a strong substance of cauterization, available in the form of a pencil with a concentration of 95 %. The tip of the pencil is directed towards the area of bleeding and action is seen in a few minutes.

Bony Haemorrhage After extraction of a tooth. hemorrhage may occur due to expansion of the socket which is hard to see because of the flow of the blood. we can stop this type of bleeding by compressing a pack, the flat plastic tool may be used to compress the bone and burnish cancellous bone.

Haemostatic gauze: Resorbable dressing availability in the clinic give the dentist the choice to pack the socket before suturing. The high risky patient of having post-operative bleeding as a complication, it is advisable to use oxidized regenerated cellulose, collagen sponge or resorbable gelatin sponge plus sutures. The use of non-resorbable dressing is less because it requires removal and this may cause disruption to the socket.

Bone wax: A softening agent which is added to paraffin and beeswax, is used as an effective measure in controlling bleeding of the bony origin. We first must be sure of the site of bleeding, pressing the wax in the spaces between bone, thus the pressure helps haemostasis. As the wax may be treated by the body as a foreign substance as it is not resorbable, wax should be removed after process of haemostasis is completed. Complete removal is hard to

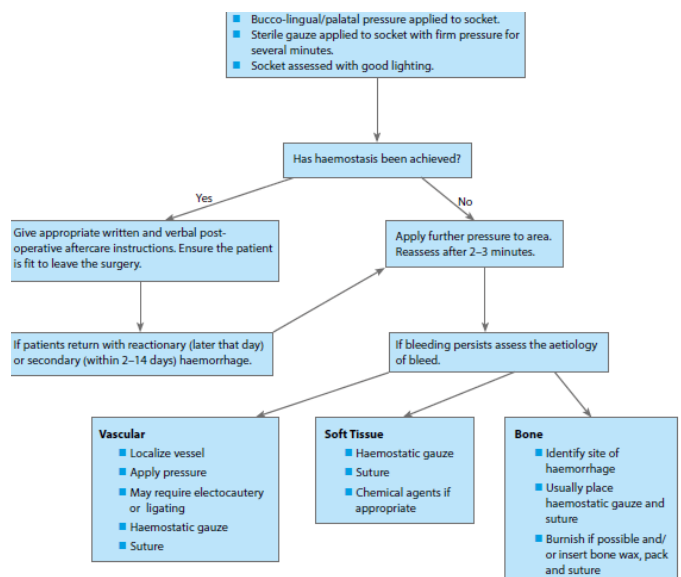


Chart 1: Management of post-extraction haemorrhage.

Electrocautery: directing the heat towards the appeared end of the vessel. The bleeder should be identified then cauterized

Drugs that affect Haemostasis:

- Indications:

Rudolph Virchow defined the risks of thromboembolisms as 3

- 1- stasis of the blood column
- 2- a damaged wall of vessels
- 3- hypercoagulability state of blood

Treatment and avoidance of thrombo-embolic diseases is the main indicator to use anticoagulants

do, so a part will always remain. After removal of wax, a gauze also should be removed and a suture is done to keep the socket pressure.

Vascular bleeding: The most annoying type of hemorrhage due to the high amount of bleeding. If bleeding was from a large vessel, Ligation of it may be required. When the bleeder is a small vessel, we can do cauterization of it. A flap may be used to allow identifying and access in cases with invisible bleeder. The dentist may feel unconfident about the site and management of the bleeder, the patient, in this case, should be referred to the department of emergency or a multifocal unit and thus needs the dentist to know the services provided in the region of his work²⁰.

Anti-platelet drugs:

- Aspirin: A (NSAIDs) that inhibits the action of cyclo-oxygenase irreversibly, that causes reduction of the productivity of thromboxane A₂ which causes vasoconstriction and platelet aggregation. However, using aspirin can reduce the rate of myocardial infarction and thus reduces mortality with a minimal side effect as GIT bleeding, although it is not used in children as it may cause Reye's syndrome.

- Dipyridamole: Blocks platelet aggregation by a reduction in the production of thromboxane A₂. Usually not used by itself, but in a combination and commonly in the avoidance measures.

- Clopidogrel: which inhibits a receptor on the cell wall of platelets and thus blocks the ADP receptors causing more activation of the platelet. Usage in avoidance of ischemic diseases in a high risky patient who had a previous myocardial infarction.

- Prasugrel and ticagrelor: They both considered an inhibitor for ADP if used with aspirin. In addition to that, prasugrel and ticagrelor are used to treat patients with the acute coronary syndrome

- Abciximab, eptifibatide, and tirofiban: they used through I.V route and works as inhibitors for glycoprotein IIb/IIIa that stops fibrinogen binding to receptors. they are used in treating angina unstable type

Oral anti-coagulants: These drugs may take about 48:72 hour to act as an inhibitor for vit.K. It is used to treat deep vein thrombosis and treat arterial fibrillation as they antagonize the formation of factors II, VII, IX and X.

Warfarin: dose must be monitored at regular periods of time to measure prothrombin time.

Dual therapy –warfarin and anti-platelet drugs: The use of anti-platelets in combination with warfarin may increase the action of warfarin as they interrupt the coagulation cascade at more than one point. plug formation will be stopped, before operations, check of INR must be done. Use of preventive measures to control bleeding as local haemostatics.

CONCLUSION

Any minor dental procedure can cause bleeding as a complication post-operatively. Management of the complication is based on how correct the diagnosis is. Referral to a local emergency unit is indicated in some cases when the bleeder is not apparent and the dentist cannot manage the case. So, a good practitioner should know the local services in the region of his work.

Nowadays, recent researches ensure that anti-coagulant therapy should not be stopped before operations as a routine like before as they show the association between the bleeding as a complication and anti-coagulant therapy not firm at all. The use of locally acting Haemostatics can help in the bleeding. Placing the gauze of hemostatic with a suitable suture should be the first line of treatment.

Novel options in anti-coagulant drugs other than antagonists of Vit.K are now highly promising.

The recent studies believe that HDD is a perfectly effective material of dressing for haemostasis. Along with its haemostatic action, it also plays a role in relieving pain.

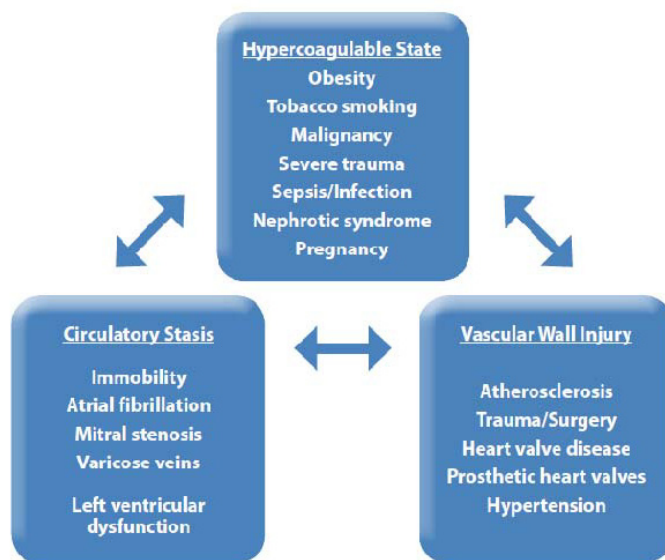
REFERENCES:

- Andersson, L., Kahnberg, K. and Pogrel, M. (2011). Oral and Maxillofacial Surgery. Hoboken: John Wiley & Sons. <http://bcs.wiley.com/he-bcs/Books?action=index&itemId=1405176237&bcsId=8965>
- Kazemi, Dr. H. Ryan (2014), EXTRACTION OF DAMAGED TEETH, retrieved February 18, 2014 https://infogalactic.com/info/Dental_extraction
- Kumar, J. (2016). Hemostasis and Post-Operative Care of Oral Surgical Wounds by Hemcon Dental Dressing in Patients on Oral Anticoagulant Therapy: A Split Mouth <https://www.ncbi.nlm.nih.gov/pubmed/27790577>
- Cocero, N., Bezzi, M., Martini, S. and Carossa, S. (2017). Oral Surgical Treatment of Patients with Chronic Liver Disease: Assessments of Bleeding and Its Relationship with Thrombocytopenia and Blood Coagulation Parameters. Journal of Oral and Maxillofacial Surgery, 75(1), pp.28-34. of bleeding and its relationship with thrombocytopenia and blood coagulation parameters. <https://www.ncbi.nlm.nih.gov/pubmed/27677683>
- Aawar, N., Alikhan, R., Bruynseels, D., Cannings-John, R., Collis, R., Dick, J., Elton, C., Fernando, R. and Hall, J. (2015). Fibrinogen concentrate versus placebo for treatment of postpartum haemorrhage: study protocol for a randomised controlled trial. Trials, 16(1). <https://www.ncbi.nlm.nih.gov/pubmed/25906770>

Chart 2: Thrombo-embolic risk factors (Virchow's Triad).

- Types of anti-thrombotic drugs: classified according to action strategy:

- 1- Anti-platelet drugs
- 2- Anti-coagulants
- 3- Thrombolytic drugs that break down the clot after it's the formation



6. Costantinides, F., Rizzo, R., Pascasio, L. and Maglione, M. (2016). Managing patients taking novel oral anticoagulants (NOAs) in dentistry: a discussion paper on clinical implications. *BMC Oral Health*, 16(1). <https://www.ncbi.nlm.nih.gov/pubmed/26822674>
7. Blinder, D., Manor, Y., Martinowitz, U. and Taicher, S. (2001). Dental extractions in patients maintained on oral anticoagulant therapy: Comparison of INR value with occurrence of postoperative bleeding. *International Journal of Oral and Maxillofacial Surgery*, 30(6), pp.518-521. <https://www.ncbi.nlm.nih.gov/pubmed/11829234>
8. Bailey, B. and Fordyce, A. (1983). Complications of dental extractions in patients receiving warfarin anticoagulant therapy. A controlled clinical trial. *British Dental Journal*, 155(9), pp.308-310. <https://www.ncbi.nlm.nih.gov/pubmed/6605757>
9. McCormick, N., Moore, U. and Meechan, J. (2014). Haemostasis Part 1: The Management of Post-Extraction Haemorrhage. *Oral Surgery*, [online] 41, pp.290-296. http://www.exodontia.info/files/Dental_Update_2014_Haemostasis_Part_1_The_Management_of_Post-Extraction_Haemorrhage.pdf
10. Madan, G., Madan, S., Madan, G. and Madan, A. (2005). Minor Oral Surgery Without Stopping Daily Low-Dose Aspirin Therapy: A Study of 51 Patients. *Journal of Oral and Maxillofacial Surgery*, 63(9), pp.1262-1265. [https://www.joms.org/article/S0278-2391\(05\)00746-9/abstract](https://www.joms.org/article/S0278-2391(05)00746-9/abstract)
11. Evans, I., Sayers, M., Gibbons, A., Price, G., Snooks, H. and Sugar, A. (2002). Can warfarin be continued during dental extraction? Results of a randomized controlled trial. *British Journal of Oral and Maxillofacial Surgery*, 40(3), pp.248-252. <https://www.sciencedirect.com/science/article/abs/pii/S0266435601907739>
12. Chee, Y., Crawford, J., Watson, H. and Greaves, M. (2008). Guidelines on the assessment of bleeding risk prior to surgery or invasive procedures. *British Journal of Haematology*, 140(5), pp.496-504. <https://onlinelibrary.wiley.com/doi/full/10.1111/j.1365-2141.2007.06968.x>
13. Ferraris VA, Swanson E. (1983) Aspirin usage and perioperative blood loss in patients undergoing unexpected operations. *Surg Gynecol Obstet*.156:439-42. <https://www.ncbi.nlm.nih.gov/pubmed/6836459>
14. Lawrence C, Sakauntabhai A, Tiling Grosse S, (1994) Effect of aspirin and nonsteroidal anti-inflammatory drug therapy on bleeding complications in dermatological surgical patients. *J Am Acad Dermatol*.31(6):988-92. <https://www.ncbi.nlm.nih.gov/pubmed/7962782>
15. Jay MP, Stephen CC, Hal OJ, Sharon WL. (2008) Hemostasis of oral surgery wounds with the hemcon dental dressings. *J Oral Maxillofac Surg*.66:1177-83. <https://www.ncbi.nlm.nih.gov/pubmed/18486782>
16. Ingram, G. (1997). The history of haemophilia*.t. *Haemophilia*, 3(S1), pp.5-15. <https://onlinelibrary.wiley.com/doi/abs/10.1111/j.1365-2516.1997.tb00168.x>
17. Tosetto, A., Castaman, G. and Rodeghiero, F. (2008). Bleeding scores in inherited bleeding disorders: clinical or research tools? *Haemophilia*, 14(3), pp.415-422. <https://onlinelibrary.wiley.com/doi/abs/10.1111/j.1365-2516.2007.01648.x>
18. Leung, L. (2006). Perioperative Evaluation of Bleeding Diathesis. *Hematology*, 2006(1), pp.457-461. <http://asheducationbook.hematologylibrary.org/content/2006/1/457.full>
19. Robinson, P. and Howe, G. (2008). Tooth extraction. Oxford: Wright.
20. Carter G, Goss A. (2003) Tranexamic acid mouthwash – a prospective randomized study of a 2-day regimen vs 5-day regimen to prevent postoperative bleeding in anticoagulated patients requiring dental extractions. *Int J Oral Maxillofac Surg* 32(5): 504–507.